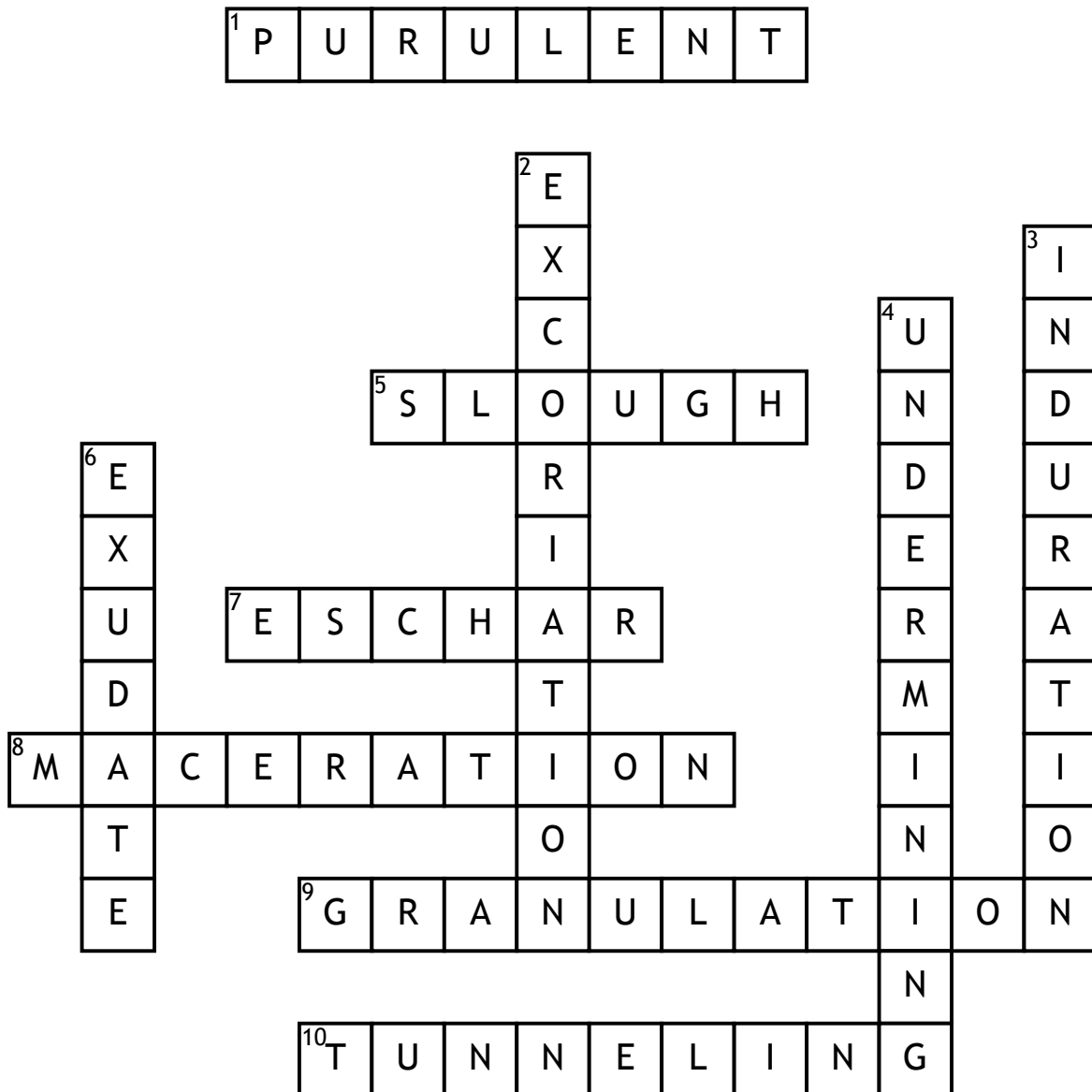


Name: \_\_\_\_\_

Date: \_\_\_\_\_

# Pressure Ulcers Wound Assessment



## Across

1. Pertaining to or consisting of pus
5. Necrotic tissue within wound that can be loose/stringy/adherence; grey/yellow/black
7. Thick necrotic tissue(dry/moist) that covers the surface of the wound
8. Softening of tissue due to excessive exudate or moisture
9. Moist tissue that is pink/red, beefy appearing with lumpy/bumpy appearance

10. a sinus tract or pathway extending from the wound surface in a single direction

## Down

2. Linear scratches on skin
3. Firm, hard tissue
4. Tissue destruction underlying intact skin along wound edges; extends in several directions
6. Wound drainage