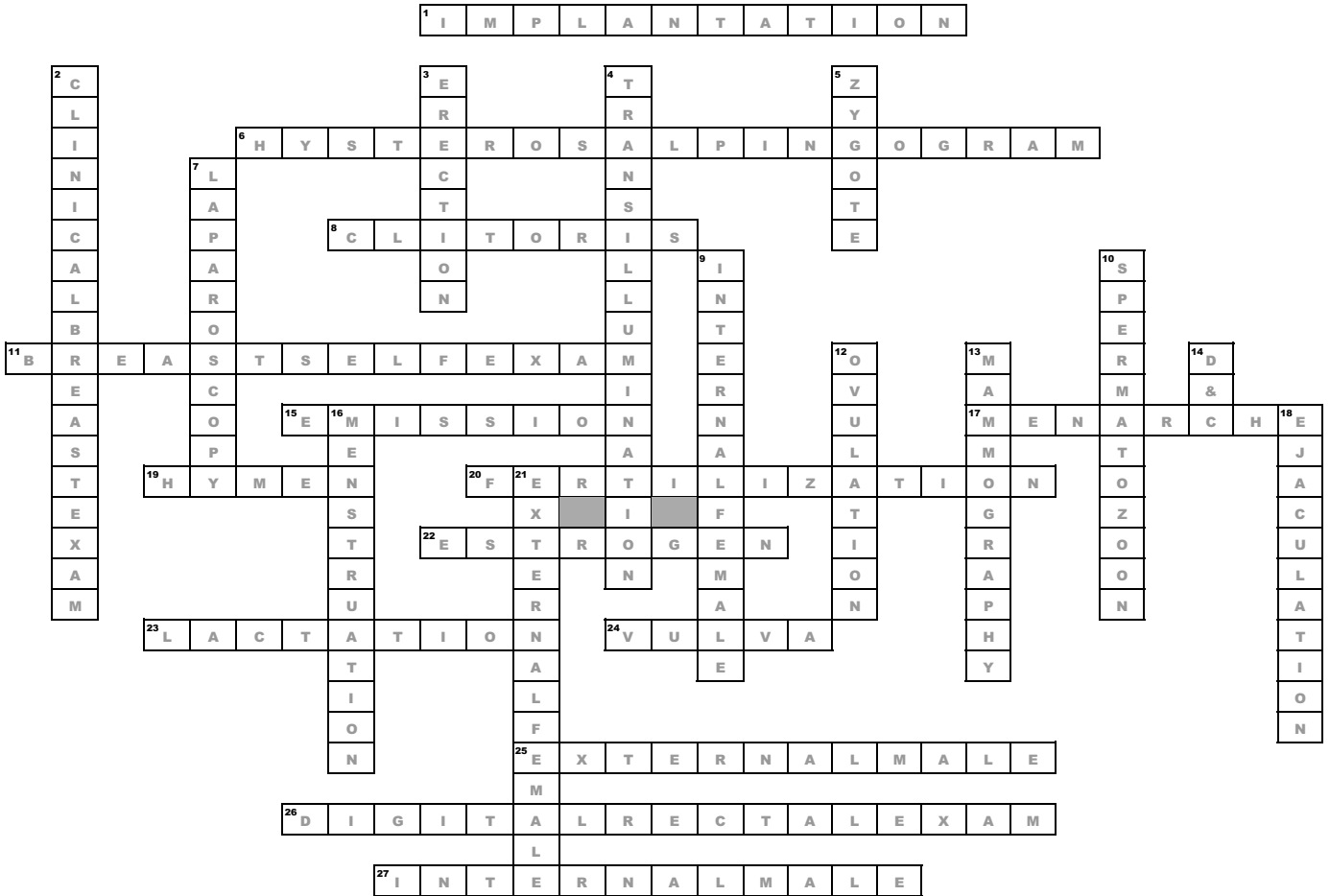


# reproductive system



**Across**

- the zygote proceeds down the uterus and attaches itself inside the endometrium
- a radiographic examination that visualizes the uterus and fallopian tubes
- erectile tissue that enlarges and becomes extremely sensitive when stimulated by the penis
- an important way for women to discover early breast changes
- the movement of sperm and their mixture to the urethra
- the first menstruation
- a mucosal membrane
- the union of ovum and sperm
- causes the development in the mammary system
- a primary function of the female breast is to produce milk
- collective term for external genitalia
- penis and scrotum
- performed to assess the prostate for size as well as evidence of tumor
- testes, seminiferous tubules, epididymis, ductus deferens and spermatic cord

**Down**

- a manual palpation of the breast performed by a physician is performed during a clients gynecologic exam before a mammogram
- a state in which the penis becomes elongated and rigid facilitating its insertion into the vagina
- shining a light through the scotum, provides clues about density of scortal tissue
- the fertilized ovum
- an examination of the interior of the abdomen to detect an ectopic pregnancy, to perform a tubal ligation, to obtain ovarian tissue for a biopsy and detect pelvic abnormalities
- vagina, uterus, two fallopian tubes, and two ovaries
- the male reproductive cell
- the expulsion of an ovum from an ovary
- a radiographic technique considered the gold standard for detecting cysts or tumors
- a surgical procedure performed in which the cervix is stretched and the endometrium is scraped
- the process that occurs when an ovum is not fertilized the production of progesterone decreases and endometrium degenerates and is shed
- the discharge of semen
- mon pubis, vaginal orifice, labia majora, labia minora, and clitoris